

Variations in Testicular Artery, Phrenic Artery and Renal Artery: A Case Series

GEETHANJALI BASAVARAJ SAVALGI¹, ROOPASHREE RAMAKRISHNA², V JAYANTHI³, H MOHAN KUMAR⁴

ABSTRACT

Anomalous blood vessels are important from the clinical aspects such as hydronephrosis, Varicocele leading to risk of infarction of kidney during renal transplant surgeries. Here, we report a case series of 30 cadavers of male and female aged between 40-80 years in the Department of Anatomy of a tertiary care institute in Bangalore, India. In three male cadavers, there was a variation in right testicular artery arising from abdominal aorta above the right renal artery later coursing downward, giving a branch to right kidney (10%). In another two male cadavers, right testicular artery (6.6%) was arising as branch of abdominal aorta above the right renal artery later coursing downward giving branch to right suprarenal gland and also observed right accessory renal artery branch of abdominal aorta arising below superior mesenteric artery and coursing upward to lower pole of right kidney. Observed in two male cadaver, inferior phrenic artery was arising as a common trunk from abdominal aorta above the main renal vessels and coursing laterally upward to diaphragm (6.6%). All the other branches of abdominal aorta and venous drainage were normal in the dissection of cadavers. The knowledge of these variations of arteries are essential before performing any transplantation surgeries, thus one can avoid the complications during urological interventions.

Keywords: Hepatocellular carcinoma, Renal surgery, Renal transplantation, Varicocele of testis, Vascular variations

INTRODUCTION

The gonadal arteries are the paired branches of the abdominal aorta emerging normally a little inferior to the renal arteries above the inferior mesenteric artery. According to the gender, they are named as testicular or ovarian artery [1]. The kidneys and gonads both develop from the intermediate mesoderm and supplied by the lateral mesonephric branches of the dorsal aorta. Caudal group of mesonephric branches give rise to gonadal artery while their persistence give rise to accessory renal artery. During the ascending of kidney and descending of gonads, they receive two main branches of mesonephric arteries, the one above and the other below. The lower branch usually atrophies when the organs reach their final position. Anomalies during the degeneration of these primitive arteries might lead to variations [2-4]. Normal pattern of gonadal artery was followed in the 83-75% to least 4.7% [5-7]. The gonadal arteries arise from the main renal arteries with a frequency which varies from 1.47-17% [5,8] while their origin from an accessory renal artery ranges from 5.5-31.25% and it occur bilaterally only in the 1.1% of cases [2,6]. In addition to the normal pattern, several other sites of origin of the gonadal artery have been described; among them the renal, accessory renal and suprarenal arteries are most commonly mentioned and more rarely from the lumbar, common iliac or internal iliac and superior epigastric artery [9]. Variation in origin of inferior phrenic arteries may arise from a common aortic origin with the coeliac trunk, from the coeliac trunk itself or from the renal artery [1]. The accessory renal artery apart from main renal artery supplying kidney arises from the main renal artery or from the aorta or from a branch of the aorta which enters the kidney at either pole [10].

CASE SERIES

An observational study was done to find any variations in branches of abdominal aorta during the routine dissection of posterior abdominal wall of 30 cadavers (20 males and 10 females) aged between 40-80 years were dissected for a period of two year in 2020 and 2021 in the Department of Anatomy, Sathagiri Institute of Medical Sciences and Research Centre, Bangalore, India. The posterior abdominal wall was dissected to find the variations in the branches of abdominal aorta.

Inclusion criteria: Cadavers with no previous history of abdominal surgery and age between 40-80 years were included in the study.

Exclusion criteria: Cadavers with previous history of abdominal surgery and with adhesions of posterior abdominal wall were excluded from the study.

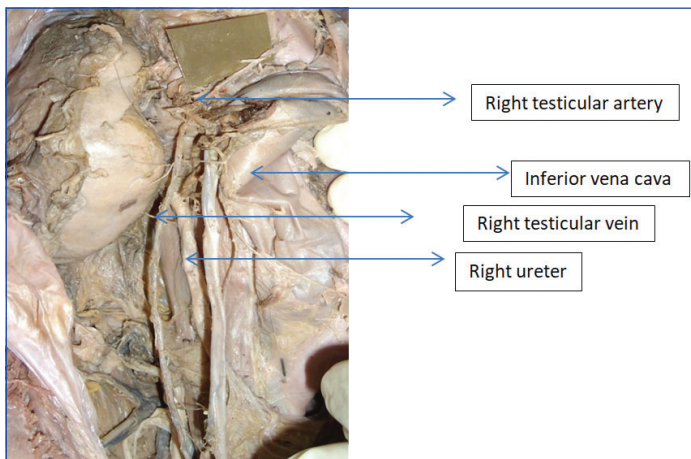
Incidence of phrenic artery, testicular artery, accessory artery was 3.3%, 6.6% and 6.6%, respectively [Table/Fig-1].

Variation in branches of abdominal aorta	Gender	Origin	Incidence
Inferior phrenic artery	Male	Origin as common trunk from Abdominal Aorta (AA)	3.3%
Testicular artery	Right side in males	Two cases origin from Abdominal Aorta above main renal artery	6.6%
Accessory renal artery crossing anterior to Inferior vena cava	Right side in males	Two cases origin from Abdominal Aorta below main renal artery	6.6%

[Table/Fig-1]: Showing the incidence of variation in the branches of abdominal aorta with respect to gender and sides.

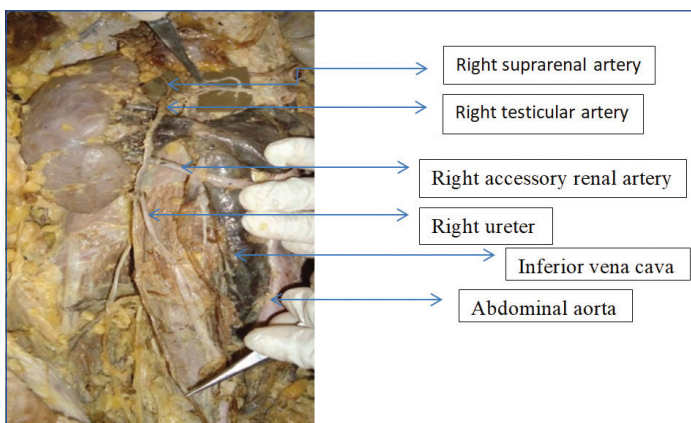
Posterior abdominal wall was dissected to find the variations in the branches of abdominal aorta after reflecting the peritoneum of posterior abdominal wall. A clean dissection of abdominal aorta and its branches were done. We observed in three male cadavers, there was a variation in right testicular artery (10%) arising from abdominal aorta above the right renal artery coursing downward giving a branch to right kidney crossing anterior to right renal vessels, right ureter and later taking normal course [Table/Fig-2].

In another two male cadavers, the authors observed that the right testicular artery (6.6%) was arising as branch of abdominal aorta above the right renal artery at the level of superior mesenteric artery giving a branch to right suprarenal gland, going downward crossing anterior to right renal vessels, right ureter and later taking normal course and also observed right accessory renal artery arising from abdominal aorta below the renal vessels, crossing anterior to inferior vena cava going to lower pole of right kidney [Table/Fig-3]. Observed in two male cadavers in which inferior phrenic artery (6.6%) was arising as a common trunk from

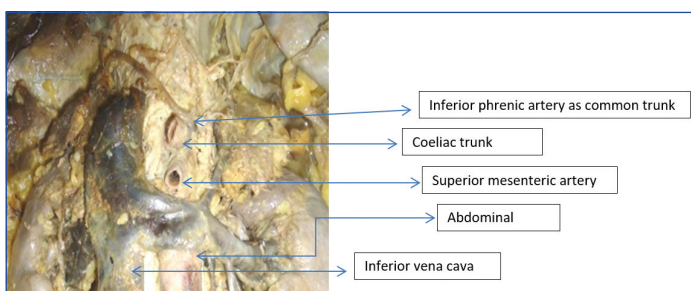


[Table/Fig-2]: High origin of right testicular artery from abdominal aorta above right renal vein, giving a branch to right kidney later running downwards crossing main right renal vessels and right ureter.

the abdominal aorta just above and lateral to coeliac trunk and above the main renal vessels [Table/Fig-4], later dividing into right and left branches to supply diaphragm. All the other branches of abdominal aorta and venous drainage were normal in the cadavers taken for the study.



[Table/Fig-3]: High origin of right gonadal artery as a branch of abdominal aorta above right renal vessels and giving branch to right suprarenal gland going downwards crossing anterior to right renal vessels, right ureter. Right accessory renal artery arising from abdominal aorta below the renal vessels crossing inferior vena cava going to inferior pole of right kidney.



[Table/Fig-4]: Right and left inferior phrenic artery arising as common trunk from Abdominal aorta above and lateral to coeliac trunk.

DISCUSSION

Normal pattern of gonadal artery was followed in 83-75% to least 4.7% [4-6]. Variation in high origin of testicular artery from abdominal aorta was as follows:

- Originating 1 cm superior to the origin of the inferior phrenic artery branched off and subdivided into a supernumerary inferior phrenic artery and a superior suprarenal artery [9]
- Originating at the level of the right renal artery [10]
- Arising from the abdominal aorta at the level of the left renal artery [11]
- High origin of the left testicular artery originating from the left renal artery [12]

- Originating from the left renal artery branch of the inferior polar artery emerging from the main renal artery on one right side or as double testicular artery.

Study showed that there was no gender related difference in the course and origin of the gonadal arteries [13]. The variations in the origin of the gonadal artery observed in spontaneously aborted fetuses was classified into four types Type 1 as origin from the suprarenal artery, Type 2 as origin from the renal artery, Type 3 as high-positional origin from the abdominal aorta, at the level of the renal artery and Type 4 as duplication of the testicular artery [8]. Notkovich H et al., described the relationship of the testicular artery to the renal vein, the anatomical variations are divided into three types [14]: Type 1 as testicular artery arising from the aorta, passing posterior or inferior to the renal vein but without making contact with it, Type 2 as testicular artery from the aorta, superior to the renal vein and crossing in front of it and Type 3 as testicular artery arising from the aorta and passing posterior or inferior to the renal vein and coursing superiorly and around the renal vein. The gonadal artery variation can also be associated with other variations in origin of coeliac trunk. Inferior phrenic artery and the accessory arteries usually arise from the aorta, above or below the main renal artery and follow it to the renal hilum [15]. The incidence of the accessory renal arteries has a wide range between 8.7% and 75.7% [16]. The inferior phrenic artery usually originates from the aorta or coeliac trunk and less frequently from the renal, hepatic or left gastric arteries. Variations in origin of the inferior phrenic artery were as common trunk in 33.3%, on the left side in 33.3% as the source of the inferior phrenic artery [3]. Rare case of inferior phrenic arteries trunk reported as originating from a common stem with a superior additional left renal artery from the abdominal aorta as revealed by routine multidetector computed tomography angiography [17]. The present case series coincide with origin of testicular artery with Cicekcibasi AE et al., studies classification type 3 as high-positional origin from the abdominal aorta, in the level of the renal artery and with Notkovich H studies classification of type 2 [2, 14]. [Table/Fig-5] showing incidence of origin of testicular artery variations with other authors [2,7,8,11-16].

Authors	No. of cadavers	Variations	Right	Left
Onderoglu S et al., [11]	66	1	1	-
Asala S et al., [7]	150	5	5	-
Bandopadhyay M and Saha A [12]	80	3	-	3
Wadhwa A and Sandeep S. [13]	30	5	2	3
Gupta A et al., [15]	30	4	2	2
Mamatha H et al., [16]	40	7	2	5
Notkovich H [14]	50	10	2	8
Cicekcibasi AE et al., [2]	-	11	7	4
Pai MM et al., [8]	34	9	4	5
Present case series	30	5	5	-

[Table/Fig-5]: Showing incidence of origin of testicular arteries variations [2,7,8,11-16].

Embryological basis: The kidneys and gonads both develop from the intermediate mesoderm and supplied from lateral mesonephric branches of the dorsal aorta. Caudal group of mesonephric branches give rise to gonadal artery while their persistence give rise to accessory renal artery. During the ascending of kidney and descending of gonads they receive two main branches of mesonephric arteries the one above and the other below. The lower branch usually atrophies when the organs reach their final position. Anomalies during the degeneration of these primitive arteries might lead to variations [8,18-20]. These anomalies may be important from the clinical point of view in that they may cause Varicocele, hydronephrosis, Nephroptosis and malrotation of the kidney.

CONCLUSION(S)

The knowledge of variations reported here is very useful for radiologists, urologists and surgeons while performing nephron-preserving surgery, kidney transplantation, and the management of renal vascular hypertension. The knowledge of these variations may also provide safety guidelines for endovascular procedures like therapeutic embolisation and angioplasties.

REFERENCES

- [1] Standring SM.(eds) Grays Anatomy 39th Ed. Edinburgh, Elsevier/Churchil Livingstone, 2005:1118-20.
- [2] Cicekcibasi AE, Salbacak A, Seker M, Ziyilan T, Büyükmumcu M, Uysal II. The origin of gonadal arteries in human fetuses: anatomical variations. *Ann Anat.* 2002;184(3):275-79.
- [3] Ozan H, Gümüşalan Y, Onderoglu S, Simsek C. High origin of gonadal arteries associated with other variations. *Ann Anat.* 1995;177(2):156-60.
- [4] Ravery V, Cussenot O, Desgrandchamps F, Teillac P, Martin-Bouyer Y, Lassau JP, et al. Variations in arterial blood supply and the risk of hemorrhage during percutaneous treatment of lesions of the pelviureteral junction obstruction: Report of a case of testicular artery arising from an inferior polar renal artery. *Surg Radiol Anat.* 1993;15(4):355-59.
- [5] Lippert H, Pabst R. Arterial variations in man. Classification and frequency. 1985.
- [6] Petru B, Elena S, Dan I, Constantin D. The morphology and the surgical importance of the gonadal arteries originating from the renal artery. *Surg Radiol Anat.* 2007;29(5):367-71.
- [7] Asala S, Chaudhary SC, Masumbuko-Kahamba N, Bidmos M. Anatomical variations in the human testicular blood vessels. *Ann Anat.* 2001;183(6):545-49.
- [8] Pai MM, Vadgaonkar R, Rai R, Nayak SR, Jiji PJ, Ranade A, et al. A cadaveric study of the testicular artery in the South Indian population. *Singapore Med J.* 2008;49(7):551-55.
- [9] Panagouli E, Lolis E, Venieratos D. Bilateral origin of the testicular arteries from the lower polar accessory renal arteries. *Int J Morphol.* 2012;30(4):1316-20.
- [10] Graves FT. Aberrant renal artery. *J Anat.* 1956 Oct; 90(Pt 4): 553-558.1.
- [11] Onderoğlu S, Yüksel M, Arik Z. Unusual branching and course of the testicular artery. *Ann Anat.* 1993;175:541-44.
- [12] Bandopadhyay M, Saha A. Three rare variations in the course of the gonadal artery. *Int J Morphol.* 2009;27(3):655-58.
- [13] Wadhwa A, Sandeep S. A study of gonadal arteries in 30 adult human cadavers. *Clinical Medicine Insights: Reproductive Health.* 2010;4:01-05.
- [14] Notkovich H. Variations of the testicular and ovarian arteries in relation to the renal pedicle. *Surg Gynecol Obstet.* 1956;103(4):487-95.
- [15] Gupta A, Singal R, Singh D. Variations of gonadal artery: Embryological basis and clinical significance. *Int J Biol Med Res.* 2011;2(4):1006-10.
- [16] Mamatha H, D'Souza AS, Vinodhini P, Ray B, Suhani, Pallavi. A cadaveric study about the anomolous origin of testicular arteries arising from the accessory renal arteries. *Indian J Surg.* 2015;77(2):111-16.
- [17] Shinohara H, Nakatani T, Fukuo Y, Morisawa S, Matsuda T. Case with high-positioned origin of the testicular artery. *Anat Rec.* 1990;226(2):264-65.
- [18] Bergman RA, Cassell MD, Sahinoglu K. Human doubled renal and testicular arteries. *Ann Anat.* 1992;174(4):313-15.
- [19] Loukas M, Stewart D. A case of an accessory testicular artery. *Folia Morphol.* 2004;63(3):355-57.
- [20] Michels NA. Embryology, topographic relations and development anomalies, observations on the blood supply of the liver and the gall bladder. In: *Blood supply and anatomy of the upper abdominal organs.* Pitman Medical Publishing Co. Ltd., London 1955;25:140.

PARTICULARS OF CONTRIBUTORS:

1. Associate Professor, Department of Anatomy, Saphthagiri Institute of Medical Sciences and Research Centre, Bangalore, Karnataka, India.
2. Professor, Department of Anatomy, East Point Medical College, Bangalore, Karnataka, India.
3. Principal and Dean, Professor, Department of Anatomy, Saphthagiri Institute of Medical Sciences and Research Centre, Bangalore, Karnataka, India.
4. Professor and Head, Department of Ophthalmology, Saphthagiri Institute of Medical Sciences and Research Centre, Bangalore, Karnataka, India.

NAME, ADDRESS, E-MAIL ID OF THE CORRESPONDING AUTHOR:

Geethanjali Basavaraj Savalgi,
No. 45, 5th Cross, Malagal, Bangalore, Karnataka, India.
E-mail: geethamohan76@gmail.com

PLAGIARISM CHECKING METHODS: [Jan H et al.]

- Plagiarism X-checker: Jul 07, 2021
- Manual Googling: Oct 30, 2021
- iThenticate Software: Nov 25, 2021 (17%)

ETYMOLOGY: Author Origin

AUTHOR DECLARATION:

- Financial or Other Competing Interests: None
- Was informed consent obtained from the subjects involved in the study? No
- For any images presented appropriate consent has been obtained from the subjects. No

Date of Submission: **Jul 06, 2021**
Date of Peer Review: **Sep 09, 2021**
Date of Acceptance: **Nov 02, 2021**
Date of Publishing: **Jan 01, 2022**